



Online article and related content
current as of December 21, 2009.

Functional Brain Imaging in a Woman With Spatial Neglect Due to Conversion Disorder

Arnaud Saj; Shahar Arzy; Patrik Vuilleumier

JAMA. 2009;302(23):2552-2554 (doi:10.1001/jama.2009.1834)

<http://jama.ama-assn.org/cgi/content/full/302/23/2552-c>

Correction

[Contact me if this article is corrected.](#)

Citations

[Contact me when this article is cited.](#)

Topic collections

Neurology; Functional Imaging; Neurology, Other; Psychiatry; Stress; Radiologic Imaging; Magnetic Resonance Imaging
[Contact me when new articles are published in these topic areas.](#)

Subscribe

<http://jama.com/subscribe>

Permissions

permissions@ama-assn.org

<http://pubs.ama-assn.org/misc/permissions.dtl>

Email Alerts

<http://jamaarchives.com/alerts>

Reprints/E-prints

reprints@ama-assn.org

In Reply: Dr Matthews highlights the issue of clean indoor air at VA facilities, one of the many pieces of unfinished business beyond those major issues that we discussed in our Commentary. We agree that all facilities where current and past military personnel serve and receive treatment should be 100% smoke-free and note the recent Institute of Medicine report *Combating Tobacco in Military and Veteran Populations*.¹

The report, which was commissioned by the Department of Defense (DOD) in 2007, calls for the DOD to set a timeline to eliminate smoking on military installations. The report also recommends that the DOD stop selling tobacco products in military commissaries and exchanges, prohibit tobacco use anywhere on military installations, and treat tobacco use in the same way as other health-related behaviors, such as alcohol abuse and poor physical fitness. We join Matthews and the Institute of Medicine in urging the VA and the DOD to take more immediate steps to protect the health of the men and women who serve in the armed services, as well as the civilians (such as Dr Matthews) working to serve them.

Jonathan Samet, MD, MS
jsamet@usc.edu
Heather Wipfli, PhD
Department of Preventive Medicine
University of Southern California
Los Angeles

Financial Disclosures: Dr Samet reported receiving honoraria from Pfizer as a member of the Pfizer Global Tobacco Advisory Board. No other disclosures were reported.

1. Bondurant S, Wedge R, eds. *Combating Tobacco Use in Military and Veteran Populations*. Washington, DC: Institute of Medicine; 2009.

Developers of the Hepatitis B Vaccine

To the Editor: In his JAMA Classics article, Dr Beasley¹ provided a commentary about the 1976 article by Buynak et al on vaccine against human hepatitis B.² However, his discussion did not include Philippe Maupas, a professor of microbiology at the Faculty of Pharmacy of Tours in France.

In 1976, Maupas published the results of the first vaccination against hepatitis B in humans.³ Patients and staff in a hemodialysis unit received an inactivated vaccine against hepatitis B (prepared from blood donor hepatitis B surface antigen purified on immunoabsorbents). Safety and efficacy had been previously tested in chimpanzees. Five years later, Maupas died in an automobile crash, returning home from the airport after a trip to Senegal, where he was conducting a trial in that endemic area to prevent hepatocellular carcinoma. Baruch Blumberg acknowledged his contribution, as well as that of Maurice Hilleman.⁴

Alain Braillon, MD
braillon.alain@chu-amiens.fr
Department of Public Health
University Hospitals
Amiens, France

Financial Disclosures: None reported.

2552 JAMA, December 16, 2009—Vol 302, No. 23 (Reprinted)

1. Beasley RP. Development of hepatitis B vaccine. *JAMA*. 2009;302(3):322-324.
2. Buynak EB, Roehm RR, Tytell AA, Bertland AU II, Lampson GP, Hilleman MR. Vaccine against human hepatitis B. *JAMA*. 1976;235(26):2832-2834.
3. Maupas P, Goudeau A, Coursaget P, Drucker J, Bagros P. Immunisation against hepatitis B in man. *Lancet*. 1976;1(7974):1367-1370.
4. Blumberg BS. Hepatitis B virus, the vaccine, and the control of primary cancer of the liver. *Proc Natl Acad Sci U S A*. 1997;94(14):7121-7125.

In Reply: Dr Braillon provides a reminder of the pioneering efforts of Philippe Maupas of the University of Tours before his sudden death in 1981. I was fortunate to have had Maupas and his colleagues as good friends in the stimulating world of early hepatitis B virus (HBV) research.

Maupas was among the many contributors to the successful development of the HBV vaccine. My commentary focused on the contributions of Maurice Hilleman and his colleagues since it was a celebration of their first publication on this successful pioneering vaccine that became the basis for the eventual World Health Organization HBV control program as the first human cancer vaccine. Other important early contributors included Saul Krugman, who was the first person to make an HBV vaccine when he showed that heat-inactivated HBV-containing sera induced a durable protective immune response; and Robert Purcell at the National Institutes of Health, who also developed an independent early HBV vaccine. The important efforts of Maupas were carried on for many years after his death by his Tours colleagues Pierre Coursaget and Alain Goudeau and became the basis of the HBV vaccine development of the Institut Pasteur in Paris.

R. Palmer Beasley, MD
r.p.beasley@uth.tmc.edu
Division of Epidemiology and Disease Control
University of Texas School of Public Health
Houston

Financial Disclosures: None reported.

RESEARCH LETTER

Functional Brain Imaging in a Woman With Spatial Neglect Due to Conversion Disorder

To the Editor: Conversion disorder is a neurological disturbance that cannot be attributed to an organic disease but arises from unconscious psychological stress.¹ Patients most often present with a motor, sensory, or visual deficit. Other cognitive symptoms such as amnesia, aphasia, or pseudodementia may also occur, but to our knowledge, spatial neglect (lateralized deficits in spatial attention typically following right-brain damage²) has not been reported in relation to conversion.¹ We describe a patient who developed a spatial neglect syndrome of conversion origin in whom brain activity was investigated by functional magnetic resonance imaging (fMRI). The patient provided written informed consent for publication of her case, and the study was approved by the ethics committee of Geneva University Hospital.

©2009 American Medical Association. All rights reserved.

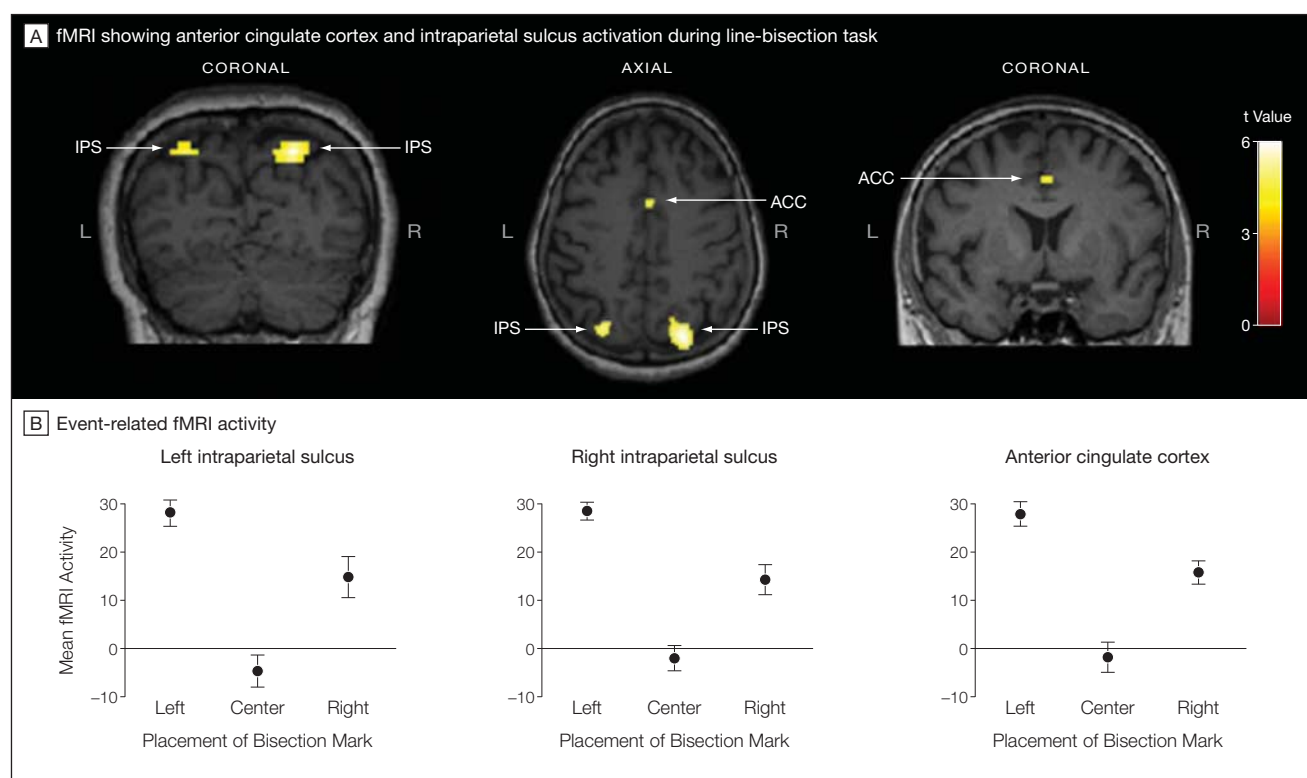
Report of a Case. A 56-year-old right-handed woman came to the hospital emergency department after briefly fainting. She was married with 5 children. She reported experiencing a poor marital relationship for many years but being too dependent on her husband to leave. Shortly after their last child left home, the patient began to develop brief episodes of dizziness and self-described disorientation. One episode occurred on the day of admission and was followed by sudden collapse with transient unresponsiveness but no convulsion.

Neurological examination showed hypoesthesia and weakness of the left arm and leg, sparing the face. Neuropsychological assessment demonstrated left spatial neglect in line-bisection and bell-cancellation tests but no other deficit (testing details available from author). Cerebral MRI, electroencephalogram, and arterial ultrasound findings were normal. Psychiatric interview indicated depressed mood and acute exacerbation of conjugal conflicts. Sensorimotor symptoms disappeared within 5 days, but spatial neglect persisted for more than 20 days and then also remitted. Based on the exclusion of an organic cause and psychiatric evaluation, the patient's deficits were diagnosed as a conversion

disorder (consistent with *Diagnostic and Statistical Manual of Mental Disorders* [Fourth Edition] criteria).

While the patient was experiencing neglect, fMRI was performed during a line-bisection task. The patient was shown pre-marked lines,³ half correctly centered and half deviated (rightward or leftward), and asked to report whether the bisection mark was placed at the midpoint (testing details available from author). Behavioral performance confirmed neglect signs with more errors for leftward-bisected (72%; 95% confidence interval [CI], 59%-85%) and centrally bisected (96%; 95% CI, 90%-100%) than rightward-bisected lines (20%; 95% CI, 9%-31%). Results from fMRI showed selective activation of the posterior parietal cortex with right predominance when comparing lines with deviated bisection (rightward or leftward) relative to centered bisection, similar to healthy persons performing comparable tasks³ (FIGURE). These findings indicate that brain systems mediating spatial attention were still differentially recruited by the left and right shifts in attention that were induced by deviated bisection marks, despite the lack of explicit report by the patient. Additional activity was also observed in the anterior cingulate cortex.

Figure. Neuroimaging in a Patient Experiencing Left Spatial Neglect Due to Conversion Disorder



Significant activation was evoked in the left (L) and right (R) intraparietal sulcus (IPS) and anterior cingulate cortex (ACC), indicated by arrows, in response to rightward and leftward shifts of the bisection marks, while there was no significant response to central bisection. A, The significance of functional magnetic resonance imaging (fMRI) activation is indicated by color-coded t values, from the least (red) to the most significant (white); all $P \leq .05$ corrected for multiple comparisons. B, Graphs plot the magnitude of event-related fMRI activity in each region of interest (mean beta value) in arbitrary units (with 95% confidence intervals, indicated by error bars) corresponding to parameter estimates of activity at each voxel, calculated by general linear model analysis and averaged across responsive voxels (using SPM2, Wellcome Department of Imaging Neuroscience, London, England; analytic details available from the author). There were no statistically significant differences between findings for left- and right-bisected lines.

Comment. The findings of this case, suggesting neglect of conversion origin, indicate that such symptoms may not simply reflect symbolic behavior or beliefs (as postulated by Freud and Breuer¹) but appear to affect cognitive processes that can be selectively disconnected from conscious awareness, as observed for neglect after organic lesions.^{1,2} The fMRI data support this hypothesis by showing preserved activation of parietal cortex (normally recruited by line bisection),³ together with increases in anterior cingulate that might relate to attention,² conflict between instructions and intentions,^{1,4} and inhibitory processes specifically related to the production of conversion.⁵

Automatic shifts of attention in both directions (indicating spontaneous and symmetric responses to lateralized stimuli), combined with no shift of attention when judging centrally bisected stimuli, point to involuntary control of attentional processes in the parietal cortex, consistent with impaired access to conscious control. This study highlights the existence of neglect symptoms due to conversion, demonstrates specific functional neuroanatomical correlates, and confirms and extends previous evidence for increased cingulate activity during conversion with other purely motor symptoms.^{5,6}

Arnaud Saj, PhD
Department of Neurology
University Hospital
Geneva, Switzerland
Shahar Arzy, MD, PhD
Department of Neurology
Hadassah Hebrew University Hospital
Jerusalem, Israel
Patrik Vuilleumier, MD
patrik.vuilleumier@unige.ch
Department of Neurosciences
Faculty of Medicine
University of Geneva
Geneva

Author Contributions: Dr Saj had full access to all of the data in the study and takes responsibility for the integrity of the data and the accuracy of the data analysis.

Study concept and design: Saj, Arzy, Vuilleumier.

Acquisition of data: Saj, Arzy, Vuilleumier.

Analysis and interpretation of data: Saj, Arzy, Vuilleumier.

Drafting of the manuscript: Saj, Arzy, Vuilleumier.

Critical revision of the manuscript for important intellectual content: Saj, Arzy, Vuilleumier.

Statistical analysis: Saj, Arzy, Vuilleumier.

Obtained funding: Vuilleumier.

Financial Disclosures: None reported.

Funding/Support: Dr Saj receives support from the Swiss National Foundation (3200B0-114014).

Role of the Sponsor: The sponsor had no role in the design and conduct of the study; in the collection, analysis, and interpretation of the data; or in the preparation, review, or approval of the manuscript.

1. Vuilleumier P. Hysterical conversion and brain function. *Prog Brain Res.* 2005; 150:309-329.
2. Mesulam MM. Spatial attention and neglect: parietal, frontal and cingulate contributions to the mental representation and attentional targeting of salient extrapersonal events. *Philos Trans R Soc Lond B Biol Sci.* 1999;354(1387):1325-1346.
3. Fink GR, Marshall JC, Shah NJ, et al. Line bisection judgments implicate right parietal cortex and cerebellum as assessed by fMRI. *Neurology.* 2000;54(6):1324-1331.
4. Aybek S, Kanaan RA, David AS. The neuropsychiatry of conversion disorder. *Curr Opin Psychiatry.* 2008;21(3):275-280.
5. Halligan PW, Athwal BS, Oakley DA, Frackowiak RS. Imaging hypnotic paralysis: implications for conversion hysteria. *Lancet.* 2000;355(9208):986-987.
6. Marshall JC, Halligan PW, Fink GR, Wade DT, Frackowiak RS. The functional anatomy of a hysterical paralysis. *Cognition.* 1997;64(1):B1-B8.

CORRECTION

Data Error in Text: In the From the Archives Journals commentary entitled "Laser Photocoagulation and Intravitreal Injection of Triamcinolone for Retinal Vein Occlusions" published in the October 21, 2009, issue of *JAMA* (2009;302[15]:1693-1695), data were incorrectly presented on the second page. In the fifth paragraph (beginning "The data from the SCORE CRVO trial"), the second sentence should read: "Approximately 27% of the participants in the 1 mg of triamcinolone group, 26% of the 4 mg of triamcinolone group, and 7% of the observation group gained 3 lines or more vision at 1 year."